

diginerve[®]
A Jaypee Initiative

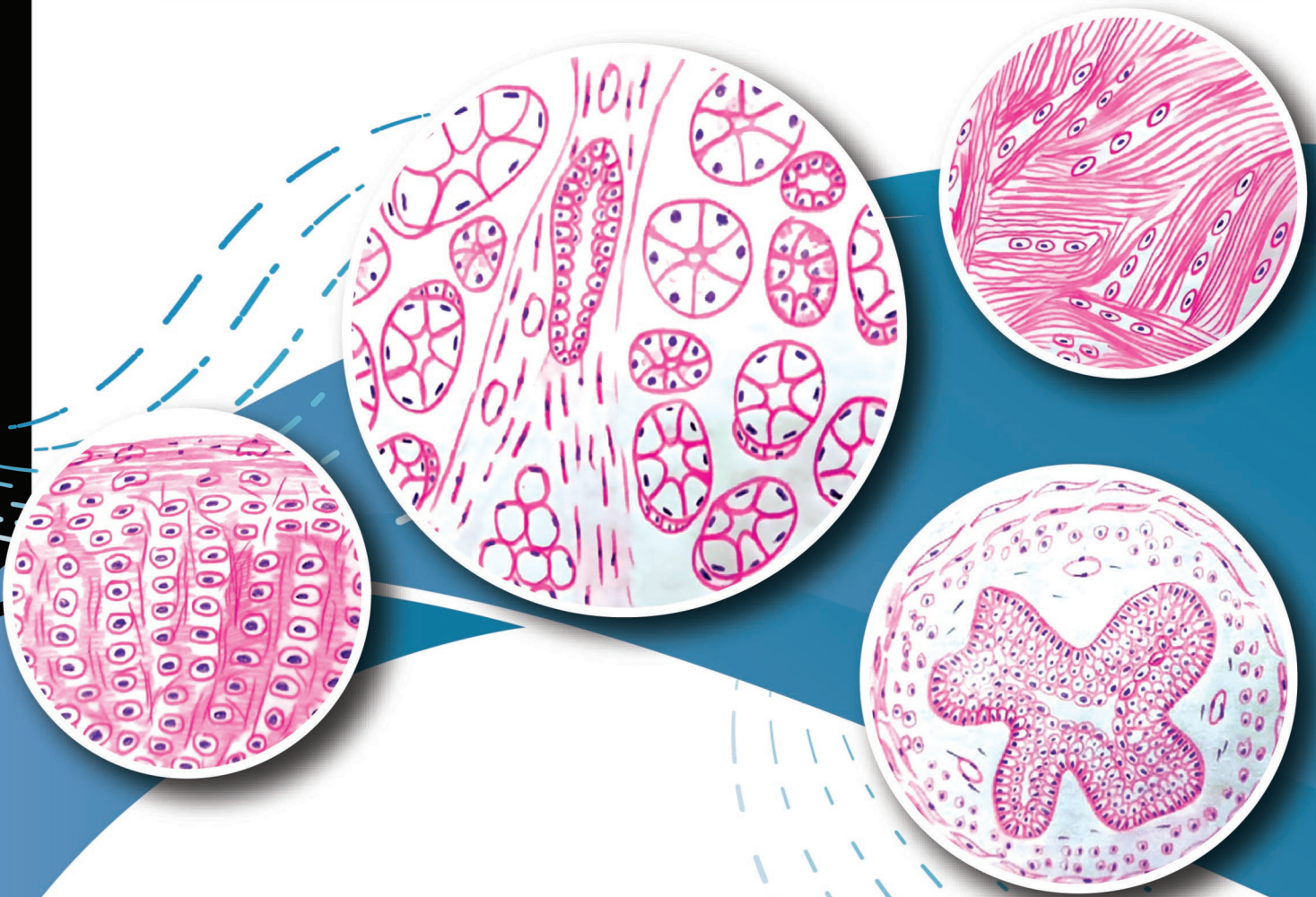

Download the App

Video Lectures | Notes | Question Bank | Dr. Wise AI Chatbot

Practical Manual of **Histology** (Workbook)

As per the Revised Competency-based Medical Education Curriculum (NMC)



Suman Yadav




JAYPEE

Contents

1. Epithelium	1
2. Connective Tissue	15
3. Cartilage	31
4. Bones	37
5. Muscular Tissue	43
6. Lymphoid Tissue	49
7. Skin	57
8. Cardiovascular System	63
9. Nervous System	69
10. Endocrine System	81
11. Respiratory System	89
12. Digestive System-I: Salivary Glands	97
13. Digestive System-II: Accessory Digestive Organs	105
14. Digestive System-III	113
15. Urinary System	131
16. Male Reproductive System	145
17. Female Reproductive System	155
18. Eye: Cornea and Retina	177

CHAPTER

10



Endocrine System

JAYPEE BROTHERS

INTRODUCTION

Endocrine system is made up of endocrine tissues. The tissue consists of endocrine cells that produce secretions called hormones which are discharged into the interstitial spaces from where they are rapidly absorbed into the blood stream

Along with the autonomic nervous system, the endocrine organs coordinate and control the metabolic activities and the internal environment of the body.

GENERAL FEATURES

- ❖ They are highly vascular with fenestrated sinusoidal capillaries.
- ❖ The secretory pole of an endocrine cell is toward the wall of a capillary or sinusoid.
- ❖ The secretory cells are characterized by prominent nucleus and well-developed organelles, especially mitochondria, endoplasmic reticulum and Golgi complex.



DISTRIBUTION OF ENDOCRINE TISSUE

Endocrine cells are distributed in three ways:

1. Discrete endocrine glands: Some organs are entirely endocrine in function. They are called endocrine glands. These are ductless glands, i.e., pituitary gland or hypophysis cerebri, thyroid, parathyroid, adrenal or suprarenal and pineal gland.
2. Endocrine tissues found in association with other organs, e.g., islet cells of Langerhans in pancreas
 - Interstitial cells of Leydig—in testis.
 - Ovarian follicle and corpus luteum—ovary
 - Chorion—in placenta
 - Lacis cells, JG cells—in kidney
3. Enteroendocrine cells—in GIT are isolated endocrine cells and called APUD cells system (amine precursor uptake and decarboxylation cell system) or neuroendocrine system.

Slide:

Dated:



JAYPEE BROTHERS

Signature

Pituitary Gland

Identifying Features

The pituitary gland is also called hypophysis cerebri. It consists of four main parts:

1. The pars nervosa or posterior is made of unmyelinated axon fibers arising from hypothalamus nuclei, supported by pituicytes and is lightly stained.
2. The pars intermedia is variable in structure. The colloid filled cysts or follicles may be seen. It is separated from pars distalis by the hypophyseal cleft.
3. The pars anterior is cellular. It consists of groups or cords of cells.

The cells of pars anterior are of three types:

- a. The pink staining cells are alpha cells or acidophils.
 - b. The cells with bluish cytoplasm are beta cells or basophils.
 - c. Cells in which the cytoplasm is not conspicuous and the nuclei are closely packed are chromophobe cells
4. Numerous sinusoids are present between the group of cells.

Thyroid Gland

Identifying Features

- ❖ The thyroid gland is composed of thyroid follicles lined by cuboidal epithelium.
- ❖ The follicles vary in shape and size.
- ❖ Each follicle is filled with a homogenous pink colloid proteinaceous material composed primarily of thyroglobulin that has been produced by the follicular epithelial cells.
- ❖ Parafollicular cells are present in relation to the follicles and also as groups in the connective tissue.
- ❖ Interfollicular connective tissue is present in the interval between the follicles.



Parathyroid Gland

Identifying Features

- ❖ These glands are made up of masses of cells with numerous capillaries in between.
- ❖ Most of the cells are the chief cells which appear as small basophilic cells.
- ❖ Oxyphilic cells appear as large eosinophilic (pink) cells.
- ❖ Oxyphil cells are few in number.
- ❖ Adipose cells are also seen.

Slide:

Dated:



JAYPEE BROTHERS

Signature

Suprarenal (Adrenal) Gland*Identifying Features*



1. The suprarenal gland is made up of a large number of cells arranged in layers
2. It consists of an outer cortex and inner medulla.
3. The cortex is divisible into three zones.
 - a. The zona glomerulosa is most superficial. It is formed by rounded or arched clusters of cells with acidophilic cytoplasm with few lipid droplets.
 - b. Zona fasciculata is formed by straight parallel cords of polyhedral cells (typically 2 cell thick), have pale cytoplasm with many lipid droplets which give it a vacuolated or spongy appearance, so these cells are also called Spongiocytes.
 - c. The zona reticularis is made up of cords of cells that branch and form a network.
4. The medulla is made up of groups of cells separated by wide sinusoids.
5. Some sympathetic neurons are also present.

Pineal Gland*Identifying Features*

1. Covered with pia mater with a capsule.
2. Presence of pinealocytes—95% pale, long processes with bulbous expansion, 5% dark staining nuclei.
3. Presence of supporting cells—astrocytes like neuroglia cells.
4. Extracellular calcified deposits of brain sand/corpora arenacea.

Slide:

Dated:



JAYPEE BROTHERS

Signature

Practical Manual of Histology (Workbook)

This textbook, focusing on histology for anatomy students, aligns with the Competency-based Medical Education (CBME) framework, enabling students to understand essential competencies in histology.

Salient Features

- Student-friendly approach with clear, concise language for easy understanding
- Clear learning objectives and competency-based learning outcomes
- Diagrams and practical exercises for enhanced visual learning and understanding
- Structured presentation in points for effortless learning and rapid revision
- Replicating practical observations of students
- Four specific identification points and one unique identification point per slide
- All topics of histology are covered as per latest CBME guidelines issued by NMC
- Helpful in preparation for histology examination and viva for undergraduate and postgraduate students

Suman Yadav MBBS MS (Anatomy) is currently working as Professor and Head, Department of Anatomy, Dr Rajender Prasad Government Medical College, Sadarpur, Himachal Pradesh, India. She completed her MBBS from SMS Medical College, Jaipur, Rajasthan, and MS from PGIMS, Rohtak, Haryana. She is former Principal of Dr Radhakrishnan Government Medical College and Hospital, Hamirpur, Himachal Pradesh. She has 33 years of experience of teaching anatomy to MBBS and MD/MS students in medical colleges. She has published 22 research papers in national and international journals. She is a compassionate teacher and admired by students. She understands the learning of anatomy through diagrammatic representation of structure of body. She is involved in implementation of new Competency-based Medical Education (CBME) curriculum in the institute.

Printed in India



Available at all medical bookstores
or buy online at www.ejaypee.com



JAYPEE BROTHERS
Medical Publishers (P) Ltd.
EMCA House, 23/23-B, Ansari Road,
Daryaganj, New Delhi - 110 002, INDIA
www.jaypeebrothers.com

Join us on [facebook.com/JaypeeMedicalPublishers](https://www.facebook.com/JaypeeMedicalPublishers)
Follow us on [instagram.com/JaypeeMedicalPublishers](https://www.instagram.com/JaypeeMedicalPublishers)

Shelving Recommendation
ANATOMY

